



A Rare Case Study on Toxic ALERD (Acute Leukoencephalopathy with Restricted Diffusion) Due To Methionine Toxicity in A Known Case of HOMOCYSTINURIA and Chronic Pancreatitis

*Ms. N. Gowthami Sunny¹, Dr. K. Siva Rama Gandhi², Dr. Mohil Soni³, Dr. M. Anu Sri Lakshmi⁴

¹ Asst. Nursing Superintendent, Apollo Hospitals, Kakinada, Andhra Pradesh-533001

² Consultant Neurophysician, Apollo Hospitals, Kakinada, Andhra Pradesh-533001

³ Neurosurgery Resident, Apollo Hospitals, Kakinada, Andhra Pradesh-533001

⁴ Clinical Care Coordinator, Apollo Hospitals, Kakinada, Andhra Pradesh-533001

DOI: [10.5281/zenodo.17438832](https://doi.org/10.5281/zenodo.17438832)

Submission Date: 03 Sept. 2025 | Published Date: 25 Oct. 2025

*Corresponding author: **Ms. N. Gowthami Sunny**

Asst. Nursing Superintendent, Apollo Hospitals, Kakinada. Andhra Pradesh-533001

Abstract

Background: Acute Leukoencephalopathy with Restricted Diffusion (ALERD) is a rare clinic radiological syndrome characterized by acute encephalopathy and diffusion restriction on MRI. While infections and toxins are known triggers, methionine-induced ALERD in patients with homocystinuria is exceedingly rare.

Case Presentation: We report a 10-year-old boy with known homocystinuria and chronic pancreatitis, presenting with headache, vomiting, and drowsiness. Initial MRI revealed chronic cerebral venous sinus thrombosis with leukodystrophy. Despite medical management, he developed acute encephalopathy with diffusion restriction and cerebral edema. Serum methionine levels were markedly elevated (1361.89 mmol/L), confirming methionine toxicity as the trigger for ALERD.

Management and Outcome: Prompt Cessation of methionine supplement which is available in Sachet Antoxipan - DS and initiation of a methionine-restricted diet, along with supportive care and steroids, led to gradual resolution of cerebral edema and neurological improvement. Nursing interventions focused on neurological monitoring, dietary management, infection prevention, and patient/family education.

Conclusion: This case highlights the importance of early recognition of methionine-induced ALERD in patients with homocystinuria, the role of neuroimaging and serum methionine monitoring, and the effectiveness of timely dietary and supportive interventions in achieving favorable outcomes.

Keywords: ALERD, SACHETANTOXIPAN-DS, methionine toxicity, homocystinuria, leukodystrophy, pediatric encephalopathy, MRI.

INTRODUCTION

Methionine Toxicity:

Acute Leukoencephalopathy with Restricted Diffusion (ALERD) is a clinic radiological syndrome characterized by acute encephalopathy and restricted diffusion on MRI, primarily in the subcortical white matter. It's an umbrella term for a range of disorders, including Acute Encephalopathy with Biphase Seizures and Late Reduced Diffusion (AESD). ALERD can be triggered by infections, toxins, and certain medications.

Bright Tree Appearance: The characteristic appearance of restricted diffusion in the white matter on MRI, resembling the branches of a tree.

Etiology: Can be caused by infections (e.g., viral infections like dengue fever), toxins (e.g., certain drugs or environmental toxins), and potentially autoimmune mechanisms.

Types of ALERD

Based on MRI findings, ALERD can be categorized into two types:

- Diffuse ALERD: Characterized by widespread areas of restricted diffusion, often associated with more severe clinical manifestations and a poorer prognosis.
- Central Sparing ALERD: Shows sparing of the central regions of the brain, particularly the primary sensorimotor cortex. This type typically has a milder phenotype and a better prognosis compared to the diffuse type.

This case study reports a rare instance of ALERD associated with methionine toxicity in a paediatric known patient of homocystinuria being treated for pancreatitis, emphasizing its clinical presentation, neuroimaging features, management, and favourable outcome, and aims to contribute to the understanding of ALERD's expanding aetiologies and the importance of timely intervention in managing this challenging condition.

DRUG INDUCED METHIONINE TOXICITY:

Patients with classic homocystinuria are at risk of Methionine Toxicity when supplemented with methionine rich edit or direct methionine supplementation.

Sachet Antoxipan-DS – which contains L- Methionine.

CASE DESCRIPTION

This 10-yr old boy known case of homocystinuria and pancreatitis brought to hospital with complaints of headache and vomiting's for 5 days. On examination he is conscious and coherent with bilateral papilledema. MRI brain showed? Chronic CSVT with leuko dystrophy. In view of papilledema and CSVT changes he was started on anticoagulants and anti-edema measures. Routine investigations were normal. Homocysteine levels were in normal range. Slowly his headache subsided, and no further vomiting noted. As he felt better, he was discharged in stable vital condition with the following medical advice.

Work up was done for all Blood investigations were sent and there was elevation in ALT(SGPT) - Serum / Plasma 68 U/L, AST (SGOT) – Serum 54 U/L.

MR VENOGRAPHY reveals S/O HYPOPLASTIC LEFT TRANSVERSE SINUS

MRI BRAIN – VENOGRAPHY reveals CEMR - BRAIN features are DIFFUSE CEREBRAL WHITE MATTER ALTERED SIGNAL INTENSITIES DUE TO SECONDARY TO DEMYELINATION.

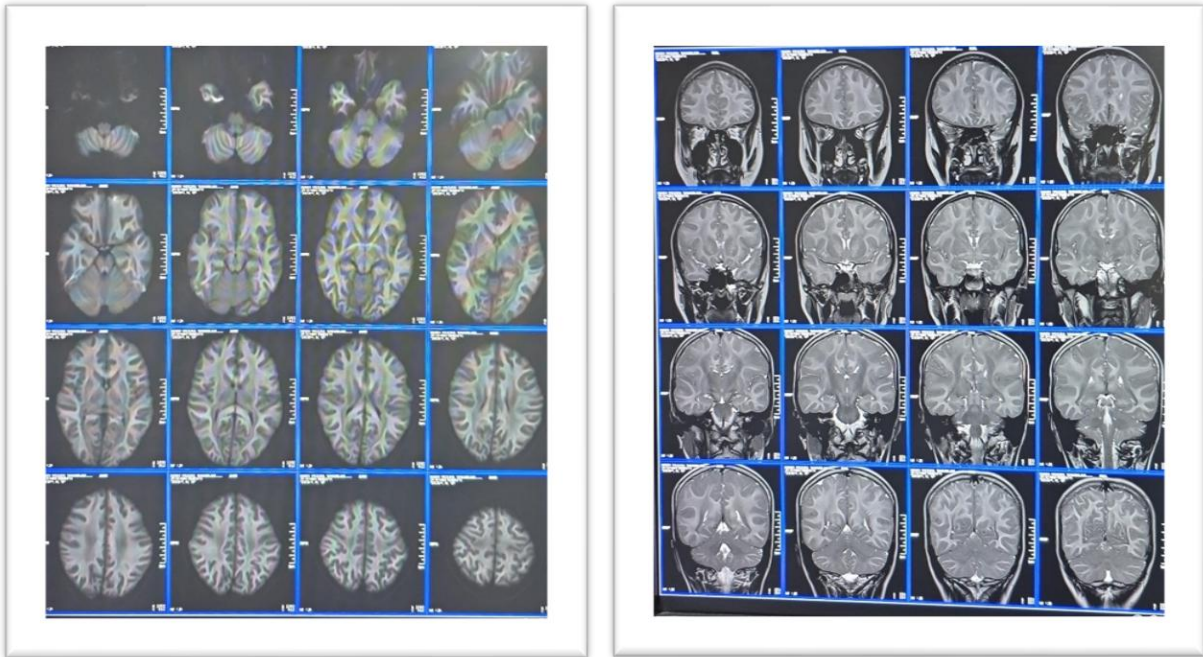
He was under medical management and Discharge with follow up medications

1. Tab. DIAMOX 250mg twice daily at 8 am – 8 pm after food for 5 days
2. Tab. MHR once daily at 9 am after breakfast
3. SACHET ANTOXIPAN – DS once daily
4. Tab. PANLIPASE once daily at 9 am after breakfast
5. Tab. ZOFER - 4mg / if required for vomiting.
6. Tab. PANTOP 40 mg once daily before breakfast
7. Tab. DABIGO 75 mg twice daily at 8 am – 8 pm after food

2nd Admission: This 10-yr old male patient known case of homocystinuria brought to ER with complaints of sudden onset of headache and vomiting for 2 days, and excess drowsiness since morning of admission. On examination he is drowsy only flexor response to DPS and pupils – bilateral equal and sluggish reaction to light. MRI brain showed acute leuko dystrophy with diffusion restriction and severe cerebral edema with herniation. He was treated with anti-edema measures and pulse dose steroids. Slowly his consciousness levels improved. Repeat MRI brain showed decreased edema and mass effect over brain stem. Serum methionine levels were sent and report awaited. As the patient felt better, he was discharged in stable vital condition with the following medical advice

At presentation, work up was done for all Blood investigations were sent for Sr. Homocysteine Sr. Albumin, Sr. Globulin, Sr. Amylase, Albumin: Globulin ratio(calculated), Sr. Alkaline Phosphate, SGOT, Bilirubin conjugated, Total bilirubin, Sr. Creatinine, Blood Urea, Random blood glucose, Sr. Lipase, Sr. Electrolytes, Sr. Protein, CBC and MRI Brain Plain was Advised.

Blood Investigation Results revealed abnormal levels of Homocysteine – 43.9 mmol/l Sr. Sodium-130mg/dl, Sr. Globulin-4.1g/dl, Albumin: Globulin ratio-0.9, Sr. Alkaline Phosphate-84u/l, SGOT-40u/l,CBC- Neutrophils-90%, Lymphocytes-08%.

MRI Brain Scan findings:

Diffuse white matter signal noted involving Bilateral Cerebral and Cerebellar Hemisphere and Brainstem.
Mild Effacement of the Ventricular system and Peri-Mesencephalic Cisterns with Crowding of Midbrain seen-
Secondary to Cerebral oedema.
Tortuous Bilateral optic nerves with prominent peri optic CSF spaces with empty Sella seen- raised ICT Features.

2nd study of MRI Brain shows:

Diffuse white matter signal noted involving Bilateral Cerebral and Cerebellar Hemisphere and Brainstem.
Mild Effacement of the Ventricular system and Peri- Mesencephalic Cisterns secondary to resolving cerebral oedema.
Tortuous Bilateral optic nerves with prominent peri optic CSF spaces with empty Sella seen- raised ICT Features.

3rd study of MRI Brain showed S/O White matter disease with restriction- secondary to acute demyelination.

He was under medical management and Discharge with follow up medications and advised for Homocysteine & Methionine Restricted Diet.

1. Continue Tab. PANLIPASE thrice daily as before
2. Sachet ANTOXIPAN-DS - 1 sachet twice daily at 8 am – 8 pm after food.
3. Tab. DIAMOX 250 mg twice daily at 8 am – 8 pm after food
4. Tab. LEVOCET 5 mg once daily at 9 pm after dinner
5. Tab. WYSOLONE 20 mg once daily at 9 am after breakfast for 2 days followed by 15 mg once daily at 8 am after breakfast for 5 days and stop.
6. Tab. FOLVITE 5 mg once daily at 2 pm after lunch
7. Tab. ZOFER - 4mg / if required for vomiting.
8. Tab. PANTOP 40 mg once daily before breakfast
9. Tab. COZIM – Q once daily at 2 pm (after lunch)
10. Tab. BENADON 40 mg twice daily at 8 am – 8 pm after food to continue
11. 11.Tab. HIFENAC – SR 100 mg ½ tab if required for neck pain

ON REGULAR OUT-PATIENT REVIEW:

During 2nd admission Serum Methionine levels were sent, in which methionine levels were found to be high 1361.89 mmol/L. On the basis of high levels of methionine, the ALERD was declared as Acute Methionine Toxicity induced.

For the Methionine Toxicity, SACHETANTOXIPAN-DS supplementation was stopped. After restricting the methionine supplementation via diet and SACHETANTOXIPAN-DS, Methionine toxicity was treated, On MRI there was resolution of cerebral edema and patient got relieved from the symptoms.

NURSING MANAGEMENT:

Highly Skilled and specialised nursing care was provided to the patient.

Assessment:

- Vitals signs were assessed on regular intervals
- Patients' Neurological status was assessed and GCS-15/15
- Assess for signs and symptoms of complications, including visual changes, skeletal abnormalities, and thromboembolic events.
- Homocysteine levels and LFT was monitored

Diagnosis:

- Risk for Ineffective tissue perfusion related to the complications of ALERD
- Risk for Injury, Imbalance Nutrition related to ALERD and Increased methionine Levels
- Risk for infection related to hospitalization

Interventions:

- Assessing Vital Signs were monitored in regular intervals and assessing Neurological status continuously
- DVT Assessment on regular interventions.
- Ensuring Fall Risk Prevention Protocols strictly.
- Regularly monitor homocysteine through blood tests as advised by the physician.
- Collaborating with a dietitian to create a personalized, low-methionine diet plan.
- Ensuring proper diet intake.
- Ensuring Medication Administration on timely basis.

Infection prevention protocols: Strict adherence to Infection control practices to prevent Hospital Acquired Infections, like Hand Hygiene-100% compliance, Regular Environmental cleaning and disinfection, Minimizing Potential Exposures (e.g., respiratory hygiene and cough etiquette).

DRUGS:

The patient was advised to continue Tab. TAXIM – O 200 mg ½ tab twice daily, Tab. PANLIPASE UC 200mg thrice daily, Tab. BENADON 40mg twice daily, Tab. FOLVIT 5mg once daily, Tab. ULTRACET 1 tab / SOS for pain, Tab. ZOFER - 4mg / if required for vomiting, Tab. PANTOP 40 mg once daily. Tab. DOLO 500mg 1 tab/ SOS.

Homocysteine & Methionine Restricted Diet.

NUTRITIONAL SUPPORT:

Patient is advised to consume the foods which are less quantity of methionine in these foods Broccoli Avocado, Potato, Brussels Sprouts, Mushrooms, Tomato, Watermelon, Kale, Eggplant, Banana, Cucumber, Lettuce, Celery, Gourd, Cranberry, Pear, Strawberry, Papaya Patient is advised to consume the foods to maintain Homocysteine levels in normal are in these foods Eat enough fish, eggs, meat, or milk, greens leafy vegetables and beans, Avoid black coffee.

FOLLOW -UP:

The child has been discharged in a stable and asymptomatic condition will all necessary instructions.

The patient was instructed to visit OPD after a week as his regular check-up post discharge to have a detailed evaluation and monitoring of any complications persisting after discharge.

The patient was advised to continue medications as prescribed and was advised Homocysteine & methionine restricted diet.

PATIENT AND FAMILY EDUCATION:

The nurse plays a vital role in educating the patient continue with your diet as advised by the Nutritionist.

Timely administration of medications as advised.

To maintain Hand Hygiene and Personal Hygiene.

Contact the Hospital immediately in case of any relevant signs and symptoms as prescribed in the Discharge Summary.

DISCUSSION:

This case illustrates the accurate diagnosis, prompt treatment and effective nursing management of Toxic ALERD due Methionine Toxicity in a known case of Homocysteinuria and Chronic Pancreatitis.

REFERENCES:

1. George, J., & Natarajan, M. (2018). Acute leukoencephalopathy with restricted diffusion: A rare clinic radiological syndrome. Indian Journal of Critical Care Medicine, 22(7), 519–523. https://doi.org/10.4103/ijccm.IJCCM_139_18

2. StatPearls. (2023). Nursing management. In StatPearls. National Center for Biotechnology Information. <https://www.ncbi.nlm.nih.gov/books/NBK593206/>
3. Ball, J. W., Dains, J. E., Flynn, J. A., Solomon, B. S., & Stewart, R. W. (2023). Vital signs and pain assessment. In J. W. Ball, J. E. Dains, J. A. Flynn, B. S. Solomon, & R. W. Stewart (Eds.), *Seidel's guide to physical examination* (10th ed., Chap. 6). Elsevier.
4. Simel, D. L. (2024). History and physical examination. In L. Goldman & K. A. Cooney (Eds.), *Goldman-Cecil medicine* (27th ed., Chap. 6). Elsevier.
5. National Institute of Neurological Disorders and Stroke. (2022, April 22). Encephalopathy. <https://www.ninds.nih.gov/health-information/disorders/encephalopathy>
6. Sacharow, S. J., Picker, J. D., & Levy, H. L. (2017). Homocystinuria caused by cystathionine beta-synthase deficiency.
7. Centers for Disease Control and Prevention. (2022). Core infection prevention and control practices for safe healthcare delivery in all settings. <https://www.cdc.gov/infection-control/hcp/core-practices/index.html>
8. Uygur, E., Aktuglu-Zeybek, C., Aghalarov, M., Cansever, M. S., Kiykim, E., & Zubarioglu, T. (2023). A Methionine-Portioning-Based Medical Nutrition Therapy with Relaxed Fruit and Vegetable Consumption in Patients with Pyridoxine-Nonresponsive Cystathionine- β -Synthase Deficiency. *Nutrients*, 15(14), 3105.
9. Food for the Brain Foundation. COG-NITION: Nutritional support. <https://foodforthebrain.org/>
10. European Network and Registry for Homocystinurias and Methylation Defects (E-HOD). (2020). Classical homocystinurias: Guidelines. https://e-hod.org/wpcontent/uploads/2020/09/CLASSICAL_HOMOCYSTINURIAS_1703_V2.pdf

CITATION

Sunny, N. G., Gandhi, K. S. R., Soni, M., & Lakshmi, M. A. S. (2025). A Rare Case Study on Toxic ALERD (Acute Leukoencephalopathy with Restricted Diffusion) Due To Methionine Toxicity in A Known Case of HOMOCYSTINURIA and Chronic Pancreatitis. In *Global Journal of Research in Medical Sciences* (Vol. 5, Number 5, pp. 84–88). <https://doi.org/10.5281/zenodo.17438832>